

Reflector-guided Localization of Non-palpable Breast Lesions: The First Reported European Evaluation of the SAVI SCOUT® System

SALIM TAYEH, SAMANTHA MUKTAR, JENNIFER HEENEY, MICHAEL J MICHELL,
NICHOLAS PERRY, TAMARA SUARIS, DAVID EVANS, ANMOL MALHOTRA and KEFAH MOKBEL

The London Breast Institute, the Princess Grace Hospital, London, U.K.

Abstract. *Background: Wire-guided localization (WGL) has been the mainstay for localizing non-palpable breast lesions before excision. Due to its limitations, various wireless alternatives have been developed. In this prospective study, we evaluate the role of radiation-free wireless localization using the SAVI SCOUT® localization at a European centre. Patients and Methods: This technique was evaluated in a prospective cohort of 20 patients. The evaluation focused on clinical and pathological parameters in addition to patient and physician acceptance. Results: SAVI SCOUT reflectors (n=23) were deployed to localize 22 occult breast lesions and one axillary lymph node in 20 patients. The mean deployment duration was 5.6 min, with a mean distance from the lesion of 0.6 mm. The migration rate was 0% and the mean identification and retrieval time was 25.1 min. In patients undergoing therapeutic excision for malignancy (n=17), only one (5.9%) required reoperation for positive surgical margins. Radiologists and surgeons rated the technique as better than WGL and patient satisfaction was high. Conclusion: Our study demonstrates that wireless localization using SAVI SCOUT® is an effective and time-efficient alternative to WGL with excellent physician and patient acceptance.*

The number of patients with non-palpable breast lesions has increased due to the widespread improvement and use of screening mammography (1). In addition, there has been an increase in the use of neoadjuvant chemotherapy (NACT) for breast cancer (2). Partial or complete response often renders breast tumours non-palpable and therefore accurate

Correspondence to: Professor K. Mokbel, The London Breast Institute, The Princess Grace Hospital, 42-52 Nottingham Place, London W1U 5NY, U.K. Tel: +44 02079082040, Fax: +44 02079082275, e-mail: kefahmokbel2@gmail.com

Key Words: SAVI SCOUT, reflector localization, non-wire localization, breast cancer.

preoperative localization of these lesions is essential in order to guide precise surgical excision.

Wire-guided localization (WGL) is currently the most widely used technique on a global scale, however, this technique has several disadvantages. It requires close coordination between the radiological and surgical departments, the insertion usually being performed on the day of surgery thus affecting radiology suite and operating theatre efficiency. The protruding wire can be bothersome for the patient, causing discomfort and anxiety. It also carries the risk of dislodgement, particularly if it is placed on the day before surgery for logistical reasons, where patient discomfort from the wire with difficulty in sleeping position, and wire dislodgement factors become of definite concern. During surgery, the wire can be transected or displaced, leading to fragment retention and possible migration. Furthermore, it can limit the surgical incision and dissection route, with a potential adverse impact on the aesthetic outcome, and can also rarely lead to potential injury to other organs such as the pleura, causing pneumothorax (3). Another potential limitation of WGL that is under-reported in the literature is the risk of needle stick injury to surgical staff caused by the sharp end of the wire. Therefore, other alternatives have been evolving to overcome these disadvantages. These include radioactive seed localization (RSL) (4), localization with a radiofrequency tag (5), and magnetic seed localization (6). Although these techniques appear to be safe and reliable alternatives to WGL, they have challenges and limitations to their use.

We previously reported our experience with the use of magnetic seed localization (Magseed®; Endomag, Cambridge, UK) and radiofrequency identification (RFID) tags (LOCALIZER™; Hologic, Santa Carla, CA, USA) in the localization of non-palpable breast lesions (7, 8). Our studies showed that these techniques were safe and effective alternatives to WGL.

SAVI SCOUT® (Cianna Medical Inc, Aliso Viejo, CA, USA) is a non-radioactive, wireless localization technique in

which a reflector is inserted into the breast lesion and reflects a combination of infra-red and radar signals from a handheld detector thereby enabling lesion localization. This device is approved by the U.S. Food and Drug Administration (FDA) for long-term placement and can be inserted at any time prior to surgery (9, 10).

In this study, we evaluated the performance of the SAVI SCOUT® system in the management of non-palpable breast lesions and report the first European experience in the use of this method.

Patients and Methods

Patients. Female patients (aged 18 years or older) with non-palpable breast lesions requiring surgical excision were enrolled in this study. The indications for surgery included screen-detected non-palpable malignancy (n=14), malignant lesions rendered non-palpable post NACT (n=4), and pathologically intermediate non-palpable lesions (B3/B4) (n=3) which required diagnostic surgical excision. This was an observational clinical evaluation; hence a formal ethical approval was not required. However, the use of this technology was approved by the multidisciplinary Breast Cancer Board of the London Breast Institute and subsequently by the clinical governance team of The Princess Grace Hospital. The technique was explained to all patients and informed consent was obtained. All cases were discussed at the local multidisciplinary consensus conference prior to and after surgery.

Procedure. The SAVI SCOUT® localization system (SSLS) (Cianna Medical Inc.) was used for all patients. SSLS consists of an implantable reflector, a detector handpiece and a console (Figure 1). The 12-mm reflector is percutaneously inserted into the breast tissue through a 16-gauge delivery needle (5-10 cm long) under image guidance (either ultrasound or stereotactic mammogram) (Figure 2). The handpiece emits pulses of infrared light and electromagnetic waves into the breast tissue and receives a radar signal back from the implanted reflector in the target lesion in real time. The pulsating infrared light modulates the reflector so that it returns a unique radar signal to the handpiece. The console processes the returned radar signal to provide audible and visual feedback, which increases in cadence and numerical readout with increasing proximity of the handpiece to the reflector, therefore guiding surgical excision.

Image-guided insertion of the reflectors into the non-palpable breast lesions was performed up to 8 days prior to surgery. After deployment, its position was checked using a post procedure mammogram. The duration of localization in minutes was recorded for every case.

Following informed written consent, 23 lesions in 20 patients were operated upon consecutively by the same surgeon. Reflectors were inserted up to 8 days before surgery using ultrasound (n=22) or stereotactic guidance (n=1). A post-deployment control mammography film was obtained in all cases in order to confirm the position of the reflector in relation to the target (Figures 3 and 4). The SAVI SCOUT® hand piece and console were used to localize the reflector and to confirm the presence of the reflector in the excised breast tissue. The duration of identification and retrieval of the reflectors including wound closure was recorded in minutes for every patient. Specimen mammography was subsequently

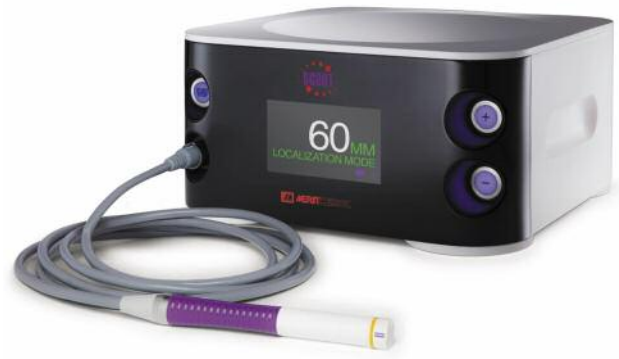

Figure 1. SAVI SCOUT® console.



Figure 2. The SAVI SCOUT® reflector. Size comparison.

performed to confirm the retrieval and position of the reflector. Specimen weight in grams was recorded for every case.

Outcome measures. The clinical and pathological parameters, the reported perceptions of the patient and the feedback from the surgeon and the radiologist were recorded. Specifically, the clinical and pathological evaluation focused on: successful deployment; successful identification and retrieval; duration of localization/insertion; duration of identification and retrieval; the weight of the resected specimen; migration rate (>5 mm) of the reflector; status of the radial surgical margins and the need for re-operation (the surgical margins were considered clear when the final radial margin was at least 2 mm away from the tumour for ductal carcinoma *in situ* and 1 mm away from the tumour for invasive cancer); patient experience and post-operative score, and surgeon's and radiologists' feedback.

Patient satisfaction with the procedure was obtained using a 10-point ascending visual analogue scale. This survey was completed after deployment of markers or surgery.

Post-operative pain score was obtained using a 10-point ascending visual analogue scale. This survey was completed on the day of surgery or during a follow up clinic.

The surgeon and the radiologists were asked to compare their experience with SAVI SCOUT® compared with WGL on a scale from neutral, better or much better.

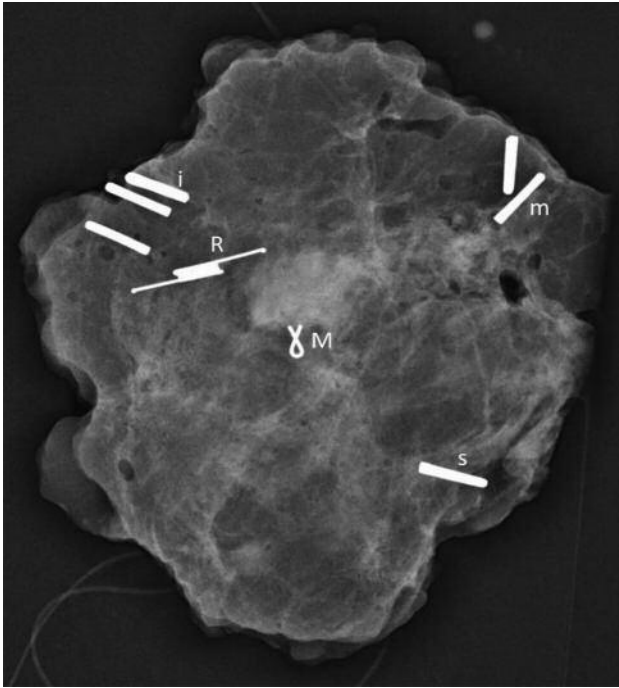


Figure 3. Specimen radiograph demonstrating the reflector (R) adjacent to the marker clip (M) in a patient who had a screen detected T1aN0 tumour and for whom the margins were clear. The titanium clips have been placed for orientation: one for superior (s); two for medial (m); three for inferior (i).

Results

A total of 23 SAVI SCOUT[®] reflectors were used to localize 22 breast lesions (19 therapeutic excisions of malignancy and four diagnostic excisions for B3 or B4 lesions) and one axillary lymph node in 20 patients (mean age=50.8 years, range=27-76 years). The reflectors were deployed under ultrasound guidance (n=22/23) or stereotactic mammogram (n=1/23) within 8 days before surgery [the mean interval until surgical excision for the cancer cases was 2.25 days (range=0-8 day)] to guide surgical excision of 22 non-palpable breast lesions and one axillary lymph node in 20 patients. All patients experienced successful deployment of the SAVI SCOUT[®] reflectors (100%). The mean duration of deployment of the reflectors was 5.6 min (median=5 min, range=1-15 min).

The mean distance between the deployed reflector and the lesion was 0.6 mm (range=0-3 mm). The rate of migration (displacement of reflector by more than 5 mm from the initial deployment position) was 0%. Identification/retrieval of the SAVI SCOUT[®] reflectors was successful in 22/23 patients (identification rate=95.7%). In one patient, the signal in the breast was detected in the radiology suite but could not be detected in the operating room. We therefore used skin marking to perform the excision and reflector retrieval

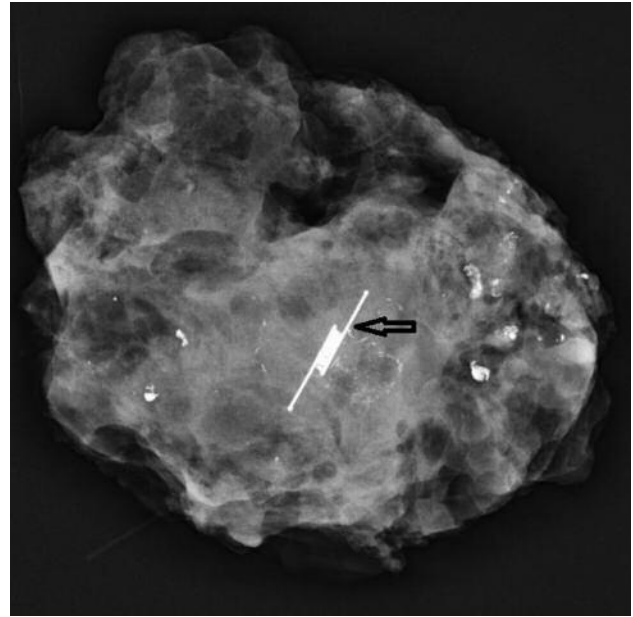


Figure 4. Specimen radiograph demonstrating the localization of malignant microcalcifications using the SAVI SCOUT[®] reflector (arrow).

successfully. We subsequently modified the protocol to include signal detection in the anaesthetic room prior to anaesthetizing the patient and ensuring the availability of a second handpiece in the operating room. The mean duration of identification and retrieval was 25.1 min (median=23 min, range=15-50 min). The recorded operating time included hemostasis, wound repair, and closure.

In patients undergoing therapeutic excision of malignant lesions (n=17), only one patient (5.9%) required reoperation for positive surgical margins. This patient therefore underwent further surgery (nipple-sparing mastectomy and immediate reconstruction). One patient had a minor wound complication in the form of superficial skin scab formation near the entry site of the stereotactic vacuum biopsy and SAVI SCOUT[®] reflector deployment that was treated conservatively and resolved spontaneously. The mean specimen weight for malignant cases was 21.1 g (median=15.3 g, range=7.5-70 g).

Patient feedback regarding their satisfaction with the experience was obtained from 17 patients, with a mean score of 9.8 out of 10 (median=10, range=9-10) using a linear visual analogue scale.

Post-operative pain score was obtained from 11 out of 17 patients with cancer using a linear visual analogue scale with a mean score of 3.1 (median=2, range=0-6). One patient developed a postoperative haematoma that required surgical evacuation and another patient (on full anticoagulation due to factor V Leiden genotype) developed a partial wound

Table I. Pathological characteristics, localization details, patient feedback and post-operative pain score in therapeutic cancer cases.

Case	Age, years	Distance of scout to target on Mammogram (mm)	Duration of deployment (min)	Duration of identification and retrieval (min)	Specimen weight (g)	Pathological TNM stage*	Margin status	Postoperative pain score (scale=0-10)	Patient satisfaction (scale=0-10)
1	52	0	5	31	20	Multifocal 18 and 16 mm/ pT1cN0	Clear	5	10
2	50	0	5	29	31	High and intermediate grade DCIS/pTis 41 mm	Clear	5	10
3	46	0	5	15	14.5	8 mm G1 IDC/pT1bN0	Clear	4.5	9
4	55	0	5	50	25	14 mm G2 IDC/pT1cN0	Clear	2	10
5	58							4.5	9
Lesion 1		0	5	11.5	9.5	24 mm G2 and 8 mm G1 IDC/	Clear		
Lesion 2		0	5	11.5	9.5	ypT2(multi)N1mic	Clear		
6	66	0	4	15	12	6 mm G1 IDC/pT1bN0	Clear	2	10
7	74	3	5	28	10.5	22 mm G2 IDC/pT2 N0	Clear	2	10
8	60	0	3	25	21.5	25 mm G3 IDC/pT2N1	Clear	Not obtained	10
9	74	0	10	38	39.5	pT1aN0	Clear	Not obtained	9
10	53	0	15	40	34	pT1cN0	Clear	2	10
11	76	0	2	19	7.5	pTis	Clear	Not obtained	10
12	50	0	3	45	11.5	ypT1N0	Clear	Not obtained	10
13	59	0	2	23	70	T1cN0	Clear	1	10
14	27	3	3	26	16	ypT0N0	Clear	0	10
15	45							Not obtained	Not obtained
Breast		3	5	20	14.5	ypT0N0	Clear		
Axilla		0	3	20					
16	36	0	4	37	19.5	T3N0	Focally positive for DCIS	Not obtained	Not obtained
17	62	4.5	15	22	13	Tis	clear	Not obtained	10

T: Tumour size; N: nodal status; p: pathology; Tis: tumour *in situ*; G: grade; DCIS: ductal carcinoma *in situ*; IDC: invasive ductal carcinoma; *The 8th Edition of the American Joint Committee on Cancer staging (34).

dehiscence that was sutured under local anaesthesia in the outpatient setting. Neither complication was specifically related to the use of Savi Scout.

The surgeon rated his experience with SAVI SCOUT[®] as much better than WGL in all 20 patients. Six radiologists rated their experience as much better (n=9/19), better (n=9/19) and neutral (n=1/19) compared to WGL.

Discussion

Although previously accepted as the mainstay of localization for impalpable breast lesions since the 1980s, wire localization has a number of pitfalls that are well recognised. These pitfalls include wire displacement; wire fragmentation; wire migration; inflexible scheduling of placement for surgery; needle stick injuries to surgeons; and of course, the discomfort and anxiety it produces for patients, many of whom have wires placed on the day of surgery. Its advantages, however, are that most breast radiologists and surgeons are well trained in their use, it is an affordable

practice and wires can be placed under magnetic resonance imaging guidance (11).

An alternative to WGL was first described by Dauway *et al.* in 1999, where they described the procedure of RSL (12). In this approach, a ¹²⁵I titanium seed is placed at the site of the lesion using radiological guidance, and is located intraoperatively by a gamma camera. The benefits of this technique included flexible scheduling, as localization can be performed up to 5 days prior to surgery, and avoidance of the discomfort associated with a protruding wire (13). Since then, subsequent studies have also shown that RSL has lower positive margin rates and can be more cost-effective than WGL (14, 15). The limitation of RSL is that, due to its radioactivity, the seeds cannot be retained for more than 5 days and should always be retrieved once deployed. Furthermore, radiation can cause local tissue damage and radioactive materials needed for this technique require special handling and disposal precautions and carry a significant regulatory burden which has to be considered when setting up an RSL service (13). The 5-day retention

Table II. *Pathological characteristics, localization details and patient feedback in diagnostic cases.*

Case	Age, years	Distance of scout to target on Mammogram (mm)	Duration of localization (min)	Duration of identification and retrieval (min)	Specimen weight (g)	Pathology	Patient satisfaction
1	58	0	1	18	7.5	Papilloma	10
2	47						
Lesion 1		0	4	19	11.5	Benign breast change	10
Lesion 2		0	4	19	13.5	Papilloma	
3	69	0	15	15	18.5	Malignant adenomyoepithelioma plus multiple papillomatosis	Not obtained

period limits its utilization in the NACT setting.

Since the evolution of wireless localization, a number of different radiation-free methods have been developed. The use of magnetic tracers was pioneered during the magnetic sentinel node and occult lesion localization (MagSNOLL) trial, which was a prospective feasibility study concerning the use of a ferromagnetic suspension in place of the radio-labelled tracer for sentinel node biopsy and tumour localization. This suspension is injected into the tumour and can then be detected intra-operatively by handheld magnetometers developed and used in this trial (16).

The MagSNOLL trial resulted in the development of magnetic seed localization (Magseed[®]; Endomag) which deploys a 5 mm seed through an 18-gauge introducer. It is now Council of Europe-marked and FDA-approved for use in patients (17, 18). The birth of this technique has meant it can be used not only to localize tumours but also pathological lymph nodes prior to commencing NACT and therefore facilitating targeted axillary dissection. The magnetic seed is physically sound and is relatively small in size (5×1 mm) compared with other non-radioactive markers. The seed can be deployed any time prior to surgery and a number of studies have shown excellent results with respect to positive margin rates and patient tolerability (18, 19). This relatively small size of the magnetic seed and narrow introducer needle (18-gauge) represent certain advantages over other similar technologies facilitating easier chip deployment in dense breasts and for small breast lesions (20). Furthermore, the introducer needle is calibrated for stereotactic deployment at the time of vacuum biopsy of malignant micro-calcifications. There are, however, limitations. The seed interferes with magnetic resonance imaging (MRI), resulting in significant artefacts, making this imaging modality void of accuracy especially when assessing response to NACT. The Magseed[®] can be accurately detected at a depth of up to 4 cm (17) but less reliably the

greater the depth, which can be potentially problematic for patients with large breasts and very deeply located tumours. Finally, all metal surgical instruments need to be removed from the surgical field when the probe is in use, which can prove tedious (11). In a pooled analysis of 1,559 Magseeds, we reported a successful placement rate of 94.42% and a successful localization rate of 99.86%; however, we found no statistically significant difference between re-excision rates using Magseeds and WGL (20).

Another approach to wireless occult breast lesion localization is the use of RFIDs. The LOCALIZERTM system by Hologic Inc. is the most recent development in the wireless localization of occult breast system and uses RFID technology. It has a current license in the European Union and United States for deployment at any time prior to surgery (8, 19). Each tag has a unique identification number that is displayed on the detecting probe, thus allowing the use of multiple tags in the same setting *e.g.* bracketing extensive microcalcifications (8). However, there are some disadvantages to this technique. Although the glass casing of the LOCALIZERTM chip prevents local tissue injury in the case of contact between the electro-cautery tool and the chip, the glass casing introduces the risk of chip migration due to its slippery surface and retention of glass fragments in the case of fracture. Furthermore, the LOCALIZERTM utilises a wider bore needle (12-gauge) than other wireless technologies, making deployment of RFID tags more challenging, especially in the presence of dense breast tissue and scarring (8).

Other wireless tumour localization methods mentioned in the literature include intra-operative ultrasound-guided, haematoma-guided, radio guided occult lesion localization combined with methylene blue dye injection, and cryo-assisted localization. These are regarded to be only of academic interest (21).

The SAVI SCOUT[®] system as used in this study is Council of Europe-marked and FDA-approved for long-term placement in breast and soft tissues (22). As previously

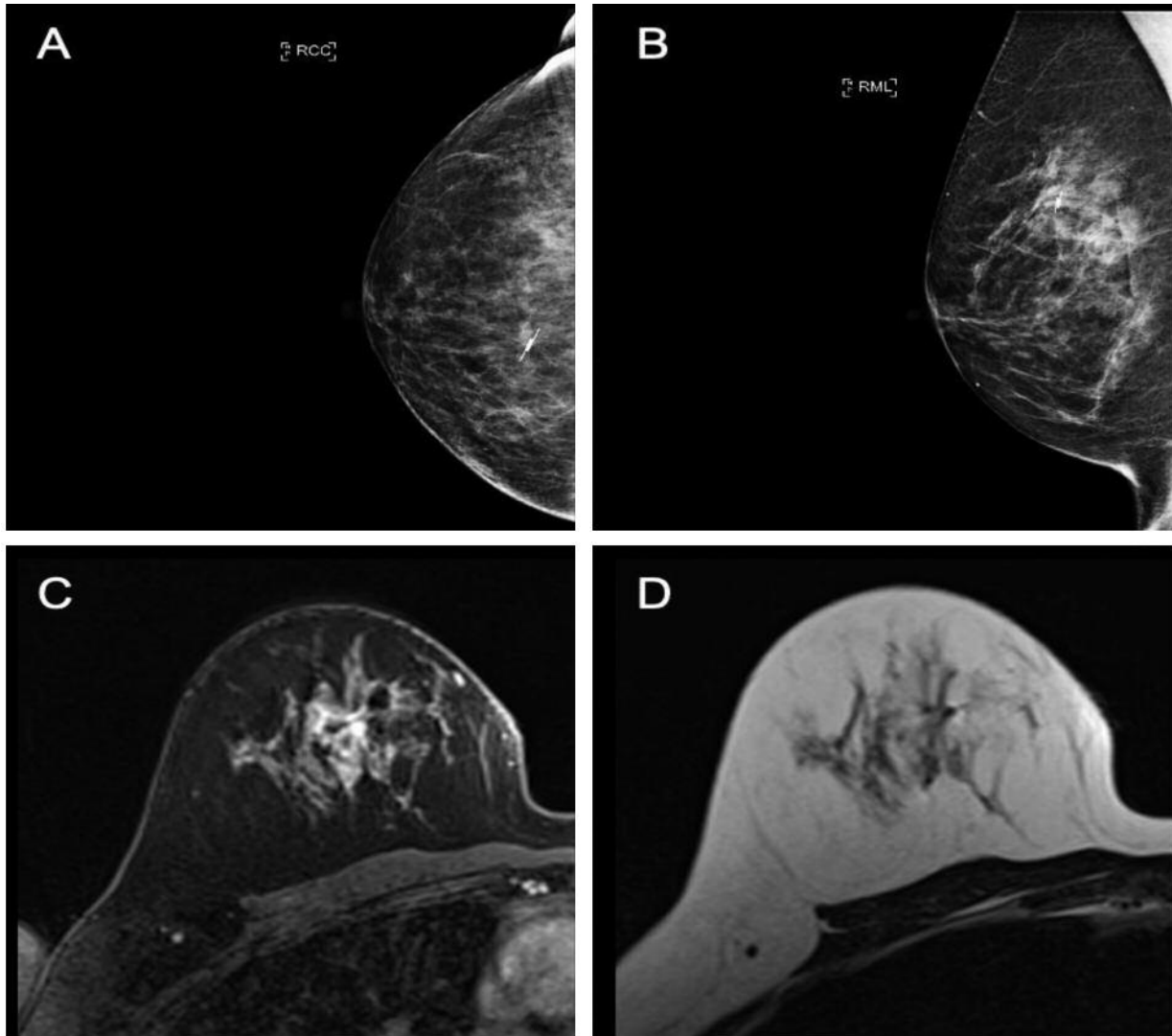


Figure 5. Minimal magnetic resonance imaging (MRI) void signals at the site of reflector localizing the tumour in the upper inner quadrant of the right breast. A: Right craniocaudal mammogram view. B: Right mediolateral mammogram view. C: T1-Weighted non-subtracted MRI image post contrast. D: T2-Weighted MRI image showing minimal MRI void.

described, the system uses a micro impulse radar reflector to achieve localization. Our report represents the first European experience using the SAVI SCOUT[®] system. We observed 100% successful deployment with a 0% migration rate. The margin positivity and reoperation rate in our study was 5.9% for malignant cases, which is significantly lower than those reported for WGL (13-21%) (3, 23, 24).

The mean weight of the excised surgical specimen in our series (21.1 g) seems to be lower than that reported for WGL (37.42 g) (25).

The mean time for successful deployment in our study was 5.6 min, which is significantly shorter than that reported

for wire localization (10 min) (26), thus resulting in time efficiency in the radiology suite, with potential cost-effectiveness implications. Another benefit of this technique that is particularly applicable to TAD and patients receiving NACT because it can be implanted any time prior to surgery (27). Furthermore, the SAVI SCOUT[®] technology produces minimal MRI void signals (less than 5 mm compared to 4 cm and 2 cm produced by Magseed[®] and RFID, respectively). This makes it suitable for deployment at the time of diagnostic biopsy in patients who are likely to require MRI to monitor responses to NACT (24), thus eliminating the need for a second invasive procedure. Two

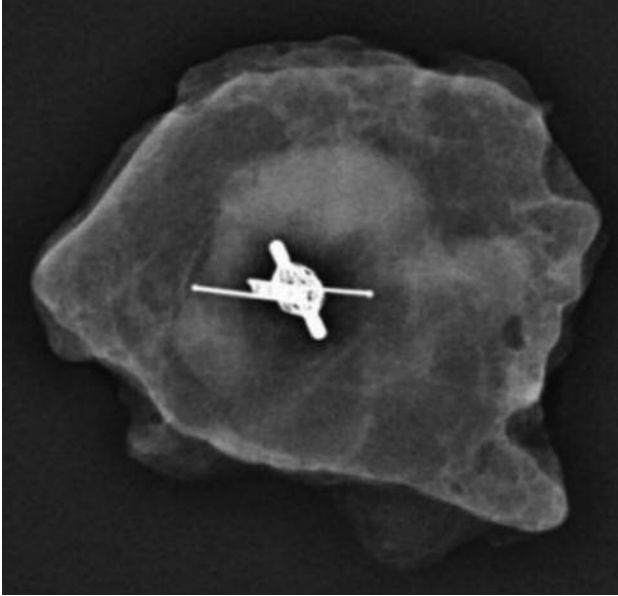


Figure 6. Specimen radiograph. Targeted axillary dissection using SAVI SCOUT® to localize the clipped node post neoadjuvant chemotherapy.

patients in our study had MRI after SAVI SCOUT® deployment: One had no void signals and one had minimal artefacts (less than 5 mm) (Figure 5).

Bloomquist *et al.* demonstrated how the reflectors can be used in targeted axillary node dissection by insertion of the reflector into clipped abnormal nodes (29). This makes the SAVI SCOUT® system an ideal localization method for patients with positive axillary lymph nodes who require NACT. One patient in our study had a SAVI SCOUT® reflector inserted into a previously clipped malignant axillary lymph node prior to commencing NACT. The reflector in this case was deployed 8 days prior to surgery since the original license limited the permitted period of deployment to within 30 days of surgery. However, since the permitted deployment period has been extended to 'long term', we now tend to insert the SAVI SCOUT® reflector at the time of suspicious lymph node biopsy, thus avoiding a second procedure. Harvesting the clipped node following NACT for biopsy-proven axillary node involvement at initial presentation reduces the false-negative rate to around 2% (30). We used SAVI SCOUT® to identify and retrieve the clipped node (Figure 6). It was as easy as using the nuclear medicine probe for identification in sentinel node biopsy. This patient achieved a pathological complete response in both breast and axilla.

Srouf *et al.* compared the SAVI SCOUT® system to WGL and RSL and observed no difference in margin positivity, specimen volume or 30-day complication rate (28). Its

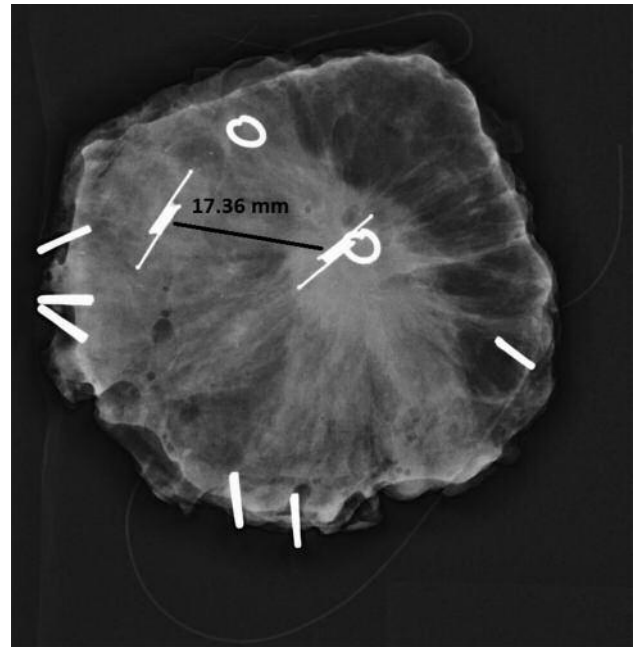


Figure 7. Specimen radiograph demonstrating the deployed reflectors under ultrasound guidance to localize two residual tumours following neoadjuvant chemotherapy. The SAVI SCOUT® console and probe were able to discriminate between the two reflectors which were 17.36 mm apart.

benefits over WGL, like other wireless techniques, is decoupling of surgery and radiology interventions and the lack of an external component, thus eliminating the possibility of displacement or transection. The real-time navigation with digital display of the distance between the probe and reflector in millimetres allows the operating surgeon to centre the targeted lesion in the middle of the specimen more accurately. This feature is not currently available in the Magseed system.

When compared to RSL, the radioactive element to this technique involves strict nuclear regulatory requirements, which can be a significant burden and limitation, eliminated by the use of SAVI SCOUT®.

The initial high cost is a potential limitation of the SAVI SCOUT® device compared with WGL; however, improved efficiency in the operating room and radiology suite may provide substantial financial savings. The SAVI SCOUT® localization system requires an initial capital purchase and a disposable purchase per procedure. Although it is substantially more expensive than WGL on a simple cost level, the total cost to the medical facility is multifactorial. Switching from WGL to SAVI SCOUT® was estimated to result in cost savings of \$1,972 per case due to reduction in operating room waiting time (31). Economic analysis should be undertaken to evaluate purchase price reimbursement over

radiology and theatre efficiency, patient satisfaction and other relevant quality metrics (32, 33).

Accurate detection using Savi Scout[®] is up to 6 cm in depth, which is greater than that for Magseed[®] and Localizer[®] (17). Its limitations include the inability to reposition the reflector once deployed, lack of MRI-compatible delivery system, nickel allergy, and intra-operative detection failure due to the presence of haematoma (17, 20, 32). It is also recognised that the reflector can be inactivated by electrocautery if the latter comes into close range. Reflector deactivation by electrocautery through short-circuiting has been reported and this seems to occur despite the fact that the reflector incorporates a specific mechanism to minimize it (27). However, this is unlikely to compromise surgical excision since in such circumstances the marker becomes visible to the operating surgeon.

In our study, the signal was detected from the surface of the skin in the operating room in 96% of cases. The single case of reflector failure observed in our study occurred prior to commencing surgery and we are unable to explain the underlying mechanism. Therefore, we have modified our protocol to safeguard against this by ensuring that there is a detectable signal in the anaesthetic room and making available a second handpiece in the operating room.

The SAVI SCOUT[®] method has been shown to be a safe, reliable and effective technique for the localization of breast cancer in several studies conducted in the United States (23, 26, 32). A study conducted by Jadeja *et al.* in 2017 also demonstrated the feasibility of using multiple reflectors in the same breast and for bracketing of large lesions (33). One patient in our study had two residual tumours following NACT which were successfully localized and excised with the SAVI SCOUT[®] system using two reflectors in the same breast (Figure 7).

We have found that this wireless breast localization technology is very helpful in the COVID-19 era when radiology resources are reduced or unpredictable on the day of surgery. Furthermore, the procedure is safer than wire insertion (closed vs. open) from a virological perspective. Since we currently tend to deploy the SAVI SCOUT[®] (no MRI void signals) at the time of tumour biopsy for highly suspicious lesions, the need for a second procedure to localize the tumour is eliminated, thereby reducing the number of hospital attendances and the potential for COVID-19 exposure.

The excellent feedback received in our study confirms the high acceptance of Savi Scout by patients and physicians. However, we acknowledge that our physician-directed questionnaire introduces inherent bias by suggesting this technology is likely to be superior to WGL.

As far as we are aware, our study is the first reported European experience of Savi Scout in breast cancer and supports the current evidence that this technique is reliable,

safe and effective. The minimal migration due to the inherent design characteristics of the reflector and absence of significant MRI void signals represent distinct advantages of the SAVI SCOUT[®] system over other wireless localization technologies such as Magseed[®] and Localizer[™].

The SAVI SCOUT[®] localization system can be improved further by the development of an introducer needle that is MRI compatible and by reducing the length of the reflector. The latter can have different designs that allow discrimination between multiple reflectors used in the same patient when bracketing large areas of microcalcifications.

We acknowledge that our study has certain limitations. It is a single-centre review with a small sample size and lacks direct comparison with WGL. A prospective randomized controlled trial would be necessary to fully compare WGL and SAVI SCOUT[®] guided localization.

Conclusion

The SAVI SCOUT[®] localization system is an accurate and reliable method for the localization of non-palpable breast lesions requiring surgical excision, with time efficiency improvement in both the radiology suite and operating theatre. It is highly accepted by patients, radiologists and surgeons.

Conflicts of Interest

None of the Authors has declared any financial conflict of interest. The manufacturer provided equipment and technology support to the London Breast Institute in order to facilitate clinical evaluation.

Authors' Contributions

KM initiated, supervised and designed the study. MJM, NP, TS, DE and AM contributed in deployment of the SAVI SCOUT and data capture. JH conducted the clinical and pathological data collection and patient's questionnaires. KM and ST conducted the data analysis. ST and SM performed a literature review and drafted the article. KM and ST proofed and finalized the manuscript.

References

- 1 DeSantis CE, Fedewa SA, Goding Sauer A, Kramer JL, Smith RA and Jemal A: Breast cancer statistics 2015: Convergence of incidence rates between Black and White women. *CA Cancer J Clin* 66(1): 31-42, 2016. PMID: 26513636. DOI: 10.3322/caac.21320
- 2 Murphy BL, Day CN, Hoskin TL, Habermann EB and Boughey JC: Neoadjuvant chemotherapy use in breast cancer is greatest in excellent responders: Triple-negative and HER2+ subtypes. *Ann Surg Oncol* 25(8): 2241-2248, 2018. PMID: 29786125. DOI: 10.1245/s10434-018-6531-5
- 3 Corsi F, Sorrentino L, Bossi D, Sartani A and Foschi D: Preoperative localization and surgical margins in conservative breast surgery. *Int J Surg Oncol* 2013: 793819, 2013. PMID: 23986868. DOI: 10.1155/2013/793819

- 4 Gray RJ, Salud C, Nguyen K, Dauway E, Friedland J, Berman C, Peltz E, Whitehead G and Cox CE: Randomized prospective evaluation of a novel technique for biopsy or lumpectomy of nonpalpable breast lesions: radioactive seed *versus* wire localization. *Ann Surg Oncol* 8(9): 711-715, 2001. PMID: 11597011. DOI: 10.1007/s10434-001-0711-3
- 5 Dauphine C, Reicher JJ, Reicher MA, Gondusky C, Khalkhali I and Kim M: A prospective clinical study to evaluate the safety and performance of wireless localization of nonpalpable breast lesions using radiofrequency identification technology. *AJR Am J Roentgenol* 204(6): W720-3, 2015. PMID: 26001262. DOI: 10.2214/AJR.14.13201
- 6 Harvey JR, Lim Y, Murphy J, Howe M, Morris J, Goyal A and Maxwell AJ: Safety and feasibility of breast lesion localization using magnetic seeds (Magseed): a multi-centre, open-label cohort study. *Breast Cancer Res Treat* 169(3): 531-536, 2018. PMID: 29453521. DOI: 10.1007/s10549-018-4709-y
- 7 Tayeh S, Gera R, Perry N, Michell M, Malhotra A and Mokbel K: The use of magnetic seeds and radiofrequency identifier tags in breast surgery for non-palpable lesions. *Anticancer Res* 40(1): 315-321, 2020. PMID: 31892582. DOI: 10.21873/anticancer.13955
- 8 Wazir U, Tayeh S, Perry N, Michell M, Malhotra A and Mokbel K: Wireless breast localization using radio-frequency identification tags: The first reported European experience in breast cancer. *In Vivo* 34(1): 233-238, 2020. PMID: 31882483. DOI: 10.21873/invivo.11765
- 9 Cianna Medical SAVI Scout Reflector and SAVI Scout System, approval from the Department of Health and human services published on the 2nd of August 2018. Available at: https://www.accessdata.fda.gov/cdrh_docs/pdf18/K181007.pdf [Last accessed the 22nd May 2020]
- 10 Press release by Cianna Medical: 'FDA clears world's first and only Wire-free radar Breast Tumour localisation System for Long Term Implant capabilities' published on the 13th of November 2017. Available at: https://www.ciannamedical.com/cianna_news_releases/fda-clears-worlds-first-wire-free-radar-breast-tumor-localization-system-long-term-implant-capabilities/ [Last accessed the 22nd May 2020]
- 11 Cheang E, Ha R, Thornton CM and Mango VL: Innovations in image-guided preoperative breast lesion localization. *Br J Radiol* 91(1085): 20170740, 2018. PMID: 29271240. DOI: 10.1259/bjr.20170740
- 12 Dauway EL, Saunders R and Friedland J: Innovative diagnostics for breast cancer: new frontiers for the new millennium using radioactive seed localization. Chicago, IL. 85th Annual American College of Surgeons Clinic Congress. American College of Surgeons, 1999.
- 13 Gray RJ, Salud C, Nguyen K, Dauway E, Friedland J, Berman C, Peltz E, Whitehead G and Cox CE: Randomized prospective evaluation of a novel technique for biopsy or lumpectomy of non-palpable breast lesions: radioactive seed *versus* wire localization. *Ann Surg Oncol* 8(9): 711-715, 2001. PMID: 11597011. DOI:10.1007/s10434-001-0711-3
- 14 Velazco CS, Wasif N, Pockaj BA and Gray RJ: Radioactive seed localization for breast conservation surgery: Low positive margin rate with no learning curve. *Am J Surg* 214(6): 1091-1093, 2017. PMID: 28947271. DOI: 10.1016/j.amjsurg.2017.08.025
- 15 Zhang Y, Seely J, Cordeiro E, Hefler J, Thavorn K, Mahajan M, Domina S, Aro J, Ibrahim AM, Arnaout A, Gravel D and Nessim C: Radioactive seed localization *versus* wire-guided localization for nonpalpable breast cancer: A cost and operating room efficiency analysis. *Ann Surg Oncol* 24(12): 3567-3573, 2017. PMID: 28913761. DOI: 10.1245/s10434-017-6084-z
- 16 Ahmed M, Anninga B, Goyal S, Young P, Pankhurst QA, Douek M and Mag STG: Magnetic sentinel node and occult lesion localization in breast cancer (MagSNOLL Trial). *Br J Surg* 102(6): 646-652, 2015. PMID: 25868072. DOI: 10.1002/bjs.9800
- 17 Hayes MK: Update on preoperative breast localization. *Radiol Clin North Am* 55(3): 591-603, 2017. PMID: 28411682. DOI:10.1016/j.rcl.2016.12.012
- 18 Zacharioudakis K, Down S, Bholah Z, Lee S, Khan T, Maxwell AJ, Howe M and Harvey J: Is the future magnetic? Magseed localisation for non-palpable breast cancer. A multi-centre non randomised control study. *Eur J Surg Oncol* 45(11): 2016-2021, 2019. PMID: 31288944. DOI: 10.1016/j.ejso.2019.06.035
- 19 Harvey JR, Lim Y, Murphy J, Howe M, Morris J, Goyal A and Maxwell AJ: Safety and feasibility of breast lesion localization using magnetic seeds (Magseed): a multi-centre, open-label cohort study. *Breast Cancer Res Treat* 169(3): 531-536, 2018. PMID: 29453521. DOI: 10.1007/s10549-018-4709-y
- 20 Gera R, Tayeh S, Al-Reefy S and Mokbel K: Evolving role of magseed in wireless localization of breast lesions: Systematic review and pooled analysis of 1,559 procedures. *Anticancer Res* 40(4): 1809-1815, 2020. PMID: 32234869. DOI: 10.21873/anticancer.14135
- 21 Chan BK, Wiseberg-Firtell JA, Jois RH, Jensen K and Audisio RA: Localization techniques for guided surgical excision of non-palpable breast lesions. *Cochrane Database Syst Rev* (12): CD009206, 2015. PMID: 26718728. DOI: 10.1002/14651858.CD009206.pub2
- 22 DiNome ML, Kusske AM, Attai DJ, Fischer CP and Hoyt AC: Microchipping the breast: an effective new technology for localizing non-palpable breast lesions for surgery. *Breast Cancer Res Treat* 175(1): 165-170, 2019. PMID: 30689105. DOI: 10.1007/s10549-019-05143
- 23 Cox CE, Garcia-Henriquez N, Glancy MJ, Whitworth P, Cox JM, Themar-Geck M, Prati R, Jung M, Russell S, Appleton K, King J and Shivers SC: Pilot study of a new nonradioactive surgical guidance technology for locating nonpalpable breast lesions. *Ann Surg Oncol* 23(6): 1824-1830, 2016. PMID: 26847680. DOI: 10.1245/s10434-015-5079-x
- 24 Hayes MK: Update on preoperative breast localization. *Radiol Clin North Am* 55(3): 591-603, 2017. PMID: 28411682. DOI: 10.1016/j.rcl.2016.12.012
- 25 Milligan R, Pieri A, Critchley A, Peace R, Lennard T, O'Donoghue JM, Howitt R, Nicholson S, Cain H, Petrides G and Sibal N: Radioactive seed localization compared with wire-guided localization of non-palpable breast carcinoma in breast conservation surgery- the first experience in the United Kingdom. *Br J Radiol* 91(1081): 20170268, 2018. PMID: 29076748. DOI: 10.1259/bjr.20170268
- 26 Tardioli S, Ballesio L, Gigli S, DI Pastena F, D'Orazi V, Giraldi G, Monti M, Amabile MI and Pasta V: Wire-guided localization in non-palpable breast cancer: results from monocentric experience. *Anticancer Res* 36(5): 2423-2427, 2016. PMID: 27127152.
- 27 Cox CE, Russell S, Prowler V, Carter E, Beard A, Mehindru A, Blumencranz P, Allen K, Portillo M, Whitworth P, Funk K, Barone J, Norton D, Schroeder J, Police A, Lin E, Combs F, Schnabel F, Toth H, Lee J, Anglin B, Nguyen M, Canavan L,

- Laidley A, Warden MJ, Prati R, King J and Shivers SC: A Prospective, single arm, multi-site, clinical evaluation of a nonradioactive surgical guidance technology for the location of nonpalpable breast lesions during excision. *Ann Surg Oncol* 23(10): 3168-3174, 2016. PMID: 27469121. DOI: 10.1245/s10434-016-5405-y
- 28 Srour MK, Kim S, Amersi F, Giuliano AE and Chung A: Comparison of wire localization, radioactive seed, and Savi scout® radar for management of surgical breast disease. *Breast J* 26(3): 406-413, 2020 PMID: 31448530. DOI: 10.1111/tbj.13499
- 29 Falcon S, Weinfurtner RJ, Mooney B and Niell BL: SAVI SCOUT® localization of breast lesions as a practical alternative to wires: Outcomes and suggestions for trouble-shooting. *Clin Imaging* 52: 280-286, 2018. PMID: 30193186. DOI: 10.1016/j.clinimag.2018.07.008
- 30 Caudle AS, Yang WT, Krishnamurthy S, Mittendorf EA, Black DM, Gilcrease MZ, Bedrosian I, Hobbs BP, DeSnyder SM, Hwang RF, Adrada BE, Shaitelman SF, Chavez-MacGregor M, Smith BD, Candelaria RP, Babiera GV, Dogan BE, Santiago L, Hunt KK and Kuerer HM: Improved axillary evaluation following neoadjuvant therapy for patients with node-positive breast cancer using selective evaluation of clipped nodes: Implementation of targeted axillary dissection. *J Clin Oncol* 34(10): 1072-1078, 2016. PMID: 26811528. DOI: 10.1200/JCO.2015.64.0094
- 31 Cleveland Clinic: Price estimates on operating waiting times. Available at: http://www.akrongeneral.org/portal/page/portal/AGMC_PAGEGROUP/Price_guide/PRICE_GUIDE5 [Last accessed 22nd May 2020]
- 32 Mango VL, Wynn RT, Feldman S, Friedlander L, Desperito E, Patel SN, Gomberawalla A and Ha R: Beyond wires and seeds: Reflector-guided breast lesion localization and excision. *Radiology* 284(2): 365-371, 2017. PMID: 28430555. DOI: 10.1148/radiol.2017161661
- 33 Jadeja PH, Mango V, Patel S, Friedlander L, Desperito E, Ayala-Bustamante E, Wynn R, Chen-Seetoo M, Taback B, Feldman S and Ha R: Utilization of multiple SAVI SCOUT surgical guidance system reflectors in the same breast: A single-institution feasibility study. *Breast J* 24(4): 531-534, 2018. PMID: 29251387. DOI: 10.1111/tbj.12979
- 34 Amin MB, Greene FL, Edge SB, Compton CC, Gershenwald JE, Brookland RK, Meyer L, Gress DM, Byrd DR and Winchester DP: The Eighth Edition AJCC Cancer Staging Manual: Continuing to build a bridge from a population-based to a more “personalized” approach to cancer staging. *CA Cancer J Clin* 67(2): 93-99, 2017. PMID: 28094848. DOI: 10.3322/caac.21388

Received May 8, 2020

Revised May 26, 2020

Accepted June 11, 2020