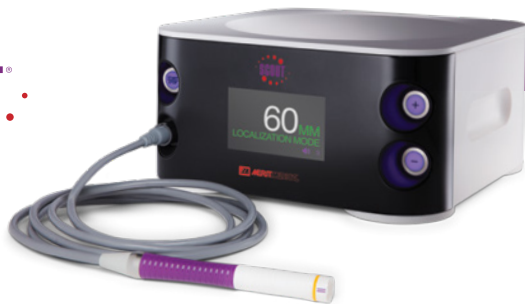



Long term SCOUT® Placement in Breast and Axillary Node Prior to Neoadjuvant Chemotherapy

Mary K. Hayes, MD
Erica V. Bloomquist, MD
Heather R. Wright MD

Departments of Radiology and Breast Surgical Oncology
Memorial Healthcare System, Hollywood, FL

Patient: 64-year-old female

Diagnosis: Locally advanced Invasive Ductal Carcinoma, Left UOQ with Left Axillary Metastasis

Rx: SCOUT localization of the left breast and left axillary lymph node was performed prior to neoadjuvant chemotherapy.

Challenge: Surgery delayed for 516 days post SCOUT localization.

Patient History

64 year-old female with locally advanced left breast IDC (hormone negative, HER-2 positive). IDC of the left breast upper outer quadrant and metastasis to left axillary lymph node had SCOUT localization at both sites (Figs. 1, 2) prior to neoadjuvant chemotherapy. She had a complete clinical response. Definitive surgery was delayed secondary to other health issues (stroke, rehabilitation, nutritional status).

Treatment Overview	
January 2018	Ultrasound-guided core biopsy A: 16 mm Left axilla lymph node marked with Bar clip METASTATIC CARCINOMA, involving portions of lymph node tissue is histologically similar to breast B: 29 mm Left breast 2 o'clock mass marked with U-shaped clip, INVASIVE DUCTAL CARCINOMA poorly differentiated (ER/PR Negative (0%); HER2 Positive).
February 2018	Ultrasound-guided SCOUT placement Breast lesion & axillary lymph node localization
July 2019	SCOUT-guided surgery Breast lesion & lymph node excision 516 days after SCOUT placement

Surgery

Planned definitive surgery was delayed secondary to health issues (stoke, rehabilitation, insurance and address changes) Patient stabilized and Pre-operative imaging confirmed complete radiologic response (Fig. 3).

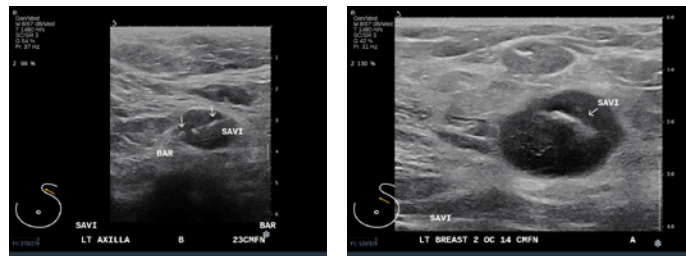


Figure 1: US-guided SCOUT Localization of the Axillary Lymph Node and Breast: February 2018

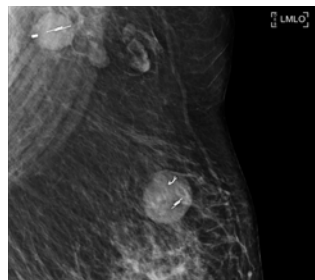


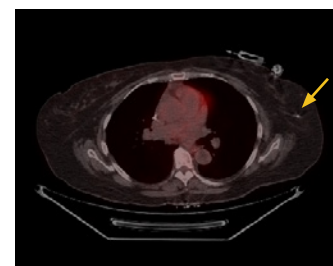
Figure 2a: Post Placement Mammogram demonstrates SCOUT in the Axillary Lymph Node and Breast.

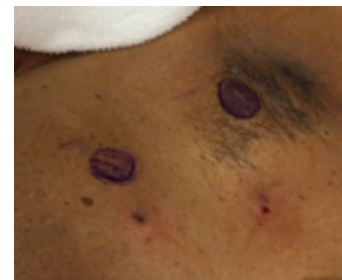

Figure 2b: Post Placement Skin Marking was performed with the patient in supine operative position, over the site of SCOUT Localization in the Axillary Lymph Node and Breast, was saved to Electronic Health Record.

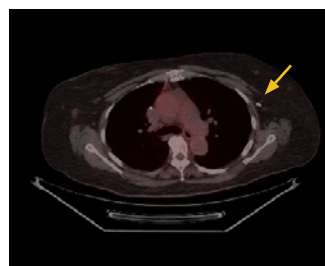

Figure 3: Preoperative Imaging PET/CT June 2019 showed no residual abnormal activity in the Axillary Lymph Node or Breast.



Definitive SCOUT-guided partial mastectomy and left axillary SCOUT-guided sentinel lymph node biopsy was performed without incident 516 days post SCOUT placement (Fig. 4).

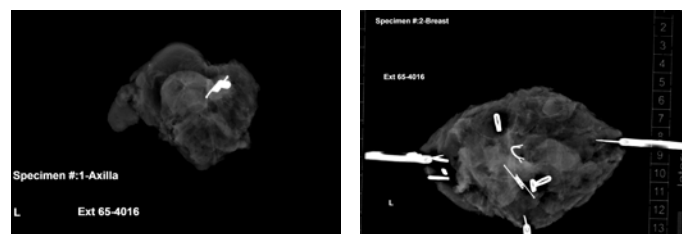


Figure 4: Specimen X-Rays of SCOUT Axillary Lymph Node (A) and Breast (B).

Postoperative Course was uneventful

Conclusion

SCOUT localization in the breast and axillary lymph node lesions can be performed prior to neoadjuvant chemotherapy when the lesion(s) are well visualized. FDA-cleared Long-term placement in the breast and axillary lymph node soft tissues allowed for 516 interval between time of SCOUT localization and definitive breast surgery in order to accommodate the patient's concomitant health care needs.



ciannamedical.com
merit.com

The foregoing case and other information are for the practitioner's convenience and for general information purposes only. This information does not constitute medical or legal advice, nor is it meant to endorse or guarantee the suitability of any of the referenced products or methods for any specific patient or procedure. Before using any product, refer to the Instructions for Use (IFU) for indications, contraindications, warnings, precautions, and directions for use.